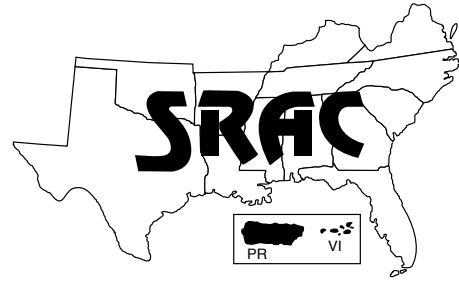


**Southern
Regional
Aquaculture
Center**



September 1998

Columnaris Disease

A Bacterial Infection Caused by *Flavobacterium columnare*

Robert M. Durborow¹, Ronald L. Thune,² John P. Hawke² and A.C. Camus²

Columnaris, first described by Herbert Spencer Davis in 1922, is one of the oldest known diseases of warm water fish. References to the disease can be confusing. The causative bacterium has been referred to by different names including *Bacillus columnaris*, *Flexibacter columnaris*, *Cytophaga columnaris*, and most recently *Flavobacterium columnare*.

Columnaris disease is the second leading cause of mortality in pond raised catfish in the southeastern United States. It is second only to enteric septicemia of catfish (ESC) caused by the bacterium *Edwardsiella ictaluri*. Most species of fish are susceptible to columnaris following some type of environmental stress and when water temperatures are in the upper part of their preferred temperature range. The disease commonly occurs in channel catfish when water temperatures are in the range of 25 to 32° C (77 to 90° F) in the spring, summer and fall.

Clinical signs or symptoms

Fish with columnaris usually have brown to yellowish-brown lesions (sores) on their gills, skin and/or fins. The bacteria attach to the gill surface, grow in spreading patches, and eventually cover individual gill filaments (Fig. 1). This results in cell death. Portions of the gills are eroded by protein- and cartilage-degrading enzymes produced by the bacteria. Skin lesions produced by columnaris initially are very shallow and may appear as an area that has lost its natural shiny appearance. More

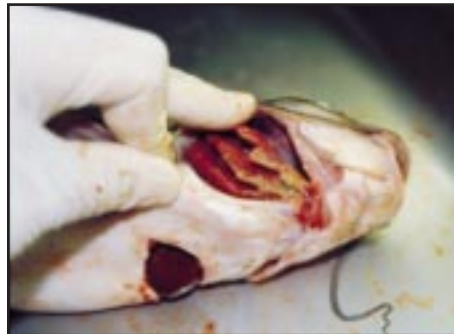

Figure 1. Yellow pigmented columnaris bacteria have infected the gills of this channel catfish, causing erosion. (Photo by Robert Durborow)

advanced lesions may be round or oval in shape, yellowish-brown in color, with an open ulcer in the center. A characteristic lesion produced by columnaris is a pale white band encircling the body, often referred to as saddleback condition (Fig. 2). As the infection progresses, a yellowish-brown ulcer often is found in the center of the "saddle." Additionally, it is not unusual to find a yellowish-brown, mucus-like growth of columnaris bacteria inside the fish's mouth (Fig. 3). The brownish coloration is usually due to mud and detritus particles trapped in the slime produced by



Figure 2. The characteristic white saddleback lesion caused by *Flavobacterium columnare* is seen on this rainbow trout fingerling. (Photo by Robert Durborow)

¹Kentucky State University Cooperative Extension Program, Frankfort, Kentucky

²Louisiana State University School of Veterinary Medicine, Baton Rouge, Louisiana



Figure 3. The yellow mucous growth of columnaris bacteria is seen in and around the mouth of this channel catfish.

the bacteria. When grown in the laboratory the bacteria produce a yellow pigment.

Columnaris can be isolated from the internal organs of fish but the significance of this is not certain. No distinct clinical signs are characteristic of these internal infections, but there may be swelling of the posterior kidney. In one study in Mississippi, columnaris was isolated internally in fish in 40 percent of the cases where it was found externally on the fish.

Cause

Columnaris bacteria probably occur in most, if not all, aquaculture environments. The bacteria can cause disease under normal culture conditions, but more likely when fish are stressed. Stressful conditions favoring columnaris disease include low oxygen, high ammonia, high nitrite, high water temperatures, rough handling, mechanical injury, and crowding. Columnaris occurs frequently in fish raised intensively in cages and in closed recirculating systems and is attributed to crowding and cage abrasions. Once established, the infection can spread quickly and cause high mortality rates.

While stressful conditions can contribute to columnaris infections, the presence of columnaris may also lead to secondary infection or other diseases. Winter saprolegniosis (also called winter fungus or winter kill) often is preceded by columnaris. In one case

study, 80 percent of catfish ponds in which winter saprolegniosis was diagnosed also had a columnaris infection in the preceding summer or fall.

Diagnosis

The presence of the brown to yellowish-brown growth of bacteria on the mouth, gills, skin or fins usually indicates an infection with *Flavobacterium columnare*. A presumptive diagnosis of columnaris is obtained by scraping an affected area on the fish, preparing a wet mount on a microscope slide, and examining it microscopically, magnified 100 to 400 times. The columnaris bacteria can be differentiated from other bacteria by their size and shape (long, thin rods, 7 to 10 millimeters and approximately 10 to 20 times longer than wide); their movement (flexing and gliding); and the formation of "haystacks" (bacterial cells that form columns on the surface of tissue). Several minutes are required for the characteristic "haystacks" to form in the wet mount slide preparation; they are best seen on fresh tissue from live fish.

Columnaris bacteria must be grown on specialized media, such as Ordal's medium, that are low in nutrient and agar content. Columnaris can be isolated from contaminated external sites and from the internal organs of fish with mixed infections by the use of selective media such as Selective Cytophaga Agar (SCA) and Hsu-Shotts (HS) medium. These media take advantage of the ability of columnaris bacteria to grow in the presence of neomycin (5 mg/l) and polymyxin B (200 units/ml), whereas most other fish pathogens and aquatic bacteria are inhibited.

Flavobacterium columnare can be identified in the laboratory by a five-step method that demonstrates:

- the ability to grow on a medium containing neomycin and polymyxin B;

- production of yellow pigmented rhizoid (root-like in appearance) colonies;
- production of a gelatin-degrading enzyme;
- binding of congo red dye to the colony; and
- production of a chondroitin sulfate-degrading enzyme.

Flavobacterium columnare are gliding bacteria that tend to randomly spread over the surface of the culture plate in a rhizoid pattern as opposed to most other bacteria which grow in small, well-defined round colonies. For a more definitive identification, specific antibodies against *F. columnare* can be used in a slide agglutination test, or molecular biological methods such as PCR (polymerase chain reaction) can be used.

Prevention and treatment

Ideally, the occurrence of columnaris could be reduced by alleviating stress on the cultured fish population. Aquaculture, however, involves stocking and feeding fish at concentrations that will ensure production efficiency and profitability. These necessary management strategies increase stressful conditions and increase the likelihood of illness in the farm-raised fish. At best, stress should be minimized as much as possible to help avoid bacterial infections such as columnaris.

Treatment for external columnaris infection includes treating the culture water with therapeutic chemicals legal for use on food fish. Potassium permanganate ($KMnO_4$) is a commonly used therapy. As of August 1998, potassium permanganate is considered on deferred status by the United States Food and Drug Administration. While it is permitted for use on food fish, it is not yet fully approved and may be made illegal in the future if new evidence finds it to be unsafe.

Potassium permanganate oxidizes organic matter and is generally used to treat external columnaris in ponds at 2 mg/l (5.4 pounds per acre-foot) or at a higher concentration if the water's organic load is high. The amount of KMnO₄ used to treat columnaris is based on the 15-minute KMnO₄ demand test. This is useful to determine the potential cost of a permanganate treatment. To conduct the test, a 500 mg/l KMnO₄ stock solution is prepared by adding 0.5 gram of KMnO₄ to 1 liter of distilled water. Then four, 1-liter beakers are each filled with 500 milliliters of the fish culture water to be treated. The KMnO₄ stock solution is added to make KMnO₄ concentrations of 1, 3, 5 and 7 milligrams per liter. To attain these concentrations, 1 milliliter of stock solution is added to the first beaker, 3 milliliters to the second, 5 milliliters to the third, and 7 milliliters to the fourth. After 15 minutes one of the four concentrations will be slightly pink and one will be clear. The concentration to select for treatment is the one that falls between these two. Multiply this concentration by a factor of 2.5, and use that concentration of KMnO₄ to treat the culture water containing the infected fish.

For example, if the beaker containing 3 mg/l KMnO₄ has a slight pink color after 15 minutes, and the beaker with 1 mg/l KMnO₄ has lost its pink color and is clear, then 2 mg/l is used and multiplied by 2.5 to obtain a treatment rate of 5 mg/l of KMnO₄. When the calculated quantity of KMnO₄ is applied to the body of water to be treated, the red color should persist for at least 4 hours.

A more traditional treatment is to dissolve 2 mg/l KMnO₄ directly in the water that needs to be treated, watching the water to ensure that it remains red for a full 4 hours. It is suggested that this treatment be applied in early morning in order to have enough daylight to observe the water

color. If the KMnO₄ oxidizes to a brown color (due to the water's organic load) before the 4-hour treatment period is reached, then an additional 2 mg/l should be added to the water. This is repeated until the red color can be maintained for the full treatment time. For maximum safety this method of treatment should be followed even if the permanganate demand of the water has been determined.

Success has been reported for treating external and internal columnaris infections with Terramycin® (oxytetracycline HCl) medicated feed. Better results are usually obtained if affected fish are treated very soon after the disease is detected. This is true especially if the disease causes the fish to eat less or stop eating entirely. Terramycin® medicated feed is administered at 25 to 37.5 milligrams of active ingredient per pound of fish for 10 days. There is a 21-day withdrawal period before fish can be sold for human consumption. **Use of Terramycin® medicated feed to control columnaris is technically an extra-label use of the drug.** Terramycin® is specifically labeled for treatment of *Aeromonas hydrophila* and *Pseudomonas* bacterial infections. Terramycin® (TM 100) has 100 grams of oxytetracycline active ingredient per pound of premix. Feed mills use the following amounts of TM 100 when manufacturing Terramycin® medicated feed and feeding rates vary according to the strength of the medicated feed mixture as shown in Table 1.

Table 1

Terramycin® (100) premix (per ton of feed)	Concentration of Terramycin® (in finished feed)	Feeding rate of fish (percent body weight)
100 lbs.	5.00 g/lb.	0.5 - 0.75 %
50 lbs.	2.50 g/lb.	1.0 - 1.5 %
25 lbs.	1.25 g/lb.	2.0 - 3.0 %

Romet*30® and Romet B® medicated feeds also should be effective in treating columnaris infections according to recent laboratory antibiotic sensitivity tests. It is, however, technically labeled for use on *Edwardsiella ictaluri* bacterial infections.

Economics

Economics must be considered when determining the best treatment procedure when fish have columnaris. Does the cost of the treatment exceed the value of the fish? Do the number of fish dying (or likely to die) have a high enough value to justify the cost of the treatment?

The following example demonstrates how economics play a role in treatment considerations.

A farmer who has a 2-acre pond stocked with 6,000, 1/2-pound catfish has lost about 40 fish a day over a week.

The fish health professional at the diagnostic laboratory has found columnaris and suggests a KMnO₄ treatment of 2 mg/l based on the KMnO₄ demand test.

The 2-acre pond averages 5 feet deep (10 acre-feet), and requires 54 pounds of KMnO₄ to get a 2 mg/l treatment (10 acre-feet X 2 mg/l X 2.7 pounds KMnO₄/acre-foot).

KMnO₄ costs about \$2 per pound, so 54 pounds would cost approximately \$108.

Assuming the fish are worth about 50 cents each, the loss totals about \$20 a day. If the mortalities continue for another 2 weeks, the farmer's losses would be about \$280.

The treatment cost of \$108 in this case appears to be economical if the treatment results are successful and mortalities stop or are significantly reduced.

If the farmer were losing only five fish per day, the cost of treatment might be more costly than the expected losses from the disease.

The economic analyses of treatment for each case should be discussed with a qualified fish health professional who has experience with many kinds of fish disease cases. This professional may be able to project the outcome of a particular disease.